

Full Length Research Article

Advancements in Life Sciences – International Quarterly Journal of Biological Sciences

ARTICLE INFO

Open Access



Date Received:
28/01/2024;
Date Revised:
08/10/2024;
Available Online:
31/12/2024;

Author's Affiliation:

1. Biomedical Sciences Doctoral Programme, Faculty of Medicine, Universitas Andalas, Padang – Indonesia
2. Otorhinolaryngology-Head and Neck Surgery Department, General Hospital of Padang Pariaman, Padang Pariaman – Indonesia
3. Otorhinolaryngology-Head and Neck Surgery Department, Faculty of Medicine, Universitas Andalas, Padang – Indonesia
4. Pathology Anatomy Department, Faculty of Medicine, Universitas Andalas, Padang – Indonesia
5. Nuclear Medicine Division of Radiology Department, Universitas Andalas, Padang – Indonesia

*Corresponding Author:

Donny Hendriyanto
Email:
donny.hendriyanto@yahoo.co.id

How to Cite:

Hendriyanto D, Rahman S, Alimuddin T, Elliyanti A (2025). Thymoquinone Protection Against Oxidative Stress Caused by Cisplatin Through Increased Superoxide Dismutase Expression in the Cochlea of Wistar Rats. Adv. Life Sci. 12(1): 231-236.

Keywords:

Antioxidants; Cisplatin; Cochlea; Oxidative stress; Rats; Thymoquinone

Editorial Note:

You are viewing the latest version of this article having minor corrections related to the use of English language and in references section.

Thymoquinone Protection Against Oxidative Stress Caused by Cisplatin Through Increased Superoxide Dismutase Expression in the Cochlea of Wistar Rats

Donny Hendriyanto^{1,2*}, Sukri Rahman³, Tofrizal Alimuddin⁴, Aisyah Elliyanti⁵

Abstract

Background: Cisplatin (Cis) is the primary and most effective chemotherapy drug for treating head and neck cancer. The side effect of cisplatin therapy is toxicity in the cochlea. The most active chemical in *Nigella sativa* (habbatussauda) is thymoquinone (TQ). The protective effects of thymoquinone antioxidants against oxidative stress caused by cisplatin in the cochlea of Wistar rats are not yet fully understood. This study aimed to determine whether thymoquinone antioxidants may protect Wistar rat cochlea from oxidative damage caused by cisplatin.

Methods: We divided 24 healthy male rats into four groups for this experimental animal study (*Rattus norvegicus*). The researchers named the group that received cisplatin alone the Cis group. The group given cisplatin and thymoquinone at 25 mg/kg/day was designated the Cis+TQ25 group. The group given cisplatin and thymoquinone at 50 mg/kg/day was designated the Cis+TQ50 group. the group that received no treatment was designated as the control group. On day 10, SOD expression was tested the expression of superoxide dismutase (SOD) in rat cochlear tissue using an immunohistochemistry examination.

Results: The Cis group significantly decreased the expression of SOD in cochlear tissue (26.64 ± 5.02) compared to the control group (64.18 ± 5.93) with a $p = 0.000$. The Cis+TQ25 group (51.95 ± 2.98) and the Cis+TQ50 group (56.19 ± 5.43) significantly increase SOD expression in cochlear tissue compared to the Cis group (26.64 ± 5.02) with a $p = 0.009$ and a $p = 0.002$.

Conclusion: Thymoquinone decreases oxidative stress caused by cisplatin by upregulating SOD expression in Wistar rat cochlea.

Introduction

Cisplatin is the primary and most effective chemotherapy drug for treating head and neck cancer [1]. The side effect of cisplatin therapy is toxicity in the cochlea (ototoxicity), which is permanent sensorineural hearing loss. The prevalence of cisplatin-induced ototoxicity remains significantly increased, ranging from 75% to 100% [2]. This hearing loss will cause communication, psychosocial, and quality of life issues for patients receiving cisplatin chemotherapy [3].

Cochlear outer hair cell (OHC) damage occurred on day three after administering cisplatin chemotherapy and reached severe damage on day 10 [4]. These observations are in line with Lin et al. [5], who demonstrated that administering cisplatin intraperitoneally (i.p.) at a dose of 15 mg/kg induces toxicity in the cochlea of rats.

Therapy for cisplatin-induced toxicity in the cochlea has, so far, not existed. *Nigella sativa*, known to Muslims as habbatussauda, is an annual herb with many pharmacological properties. Research conducted by Abdulbaki and Al-Deeb [6] discovered that thymoquinone is the most active chemical compound found in *Nigella sativa*, as depicted in Figure 1. Thymoquinone compounds are still unknown to the general public. Researchers do not clearly understand the antioxidant benefits of thymoquinone in preventing cisplatin-induced toxicity in the cochlea. Thymoquinone has been discovered by researchers to be a potent antioxidant ($IC_{50} = 80.43 \mu\text{g/mL}$) that may also eliminate free radicals to prevent tissue apoptosis [7,8]. Oral thymoquinone administered to male and female rats at doses between 10 and 100 mg/kg did not cause toxicity or death [9].




Figure 1: The most active chemical ingredient in *Nigella sativa* is thymoquinone.

One molecular target that aids thymoquinone in preventing cisplatin-induced cochlear damage or ototoxicity is antioxidant enzymes [10]. a key endogenous antioxidant enzyme in the human body is superoxide dismutase (SOD). It is the first defense against oxidative stress [11]. Evaluation of SOD expression serves as a reliable indicator for measuring

the level of oxidative stress in cochlear tissue [12]. This study aimed to evaluate how well thymoquinone antioxidants reduce oxidative damage caused by cisplatin. This will be achieved by examining in SOD expression within the cochlear tissue of Wistar rats.

Methods

Study design and animal model

This experimental animal study was conducted in June 2023 at the Medicine Faculty of Andalas University in Padang. The Research Ethics Committee of Medicine Faculty Andalas University in Padang deemed this study ethically viable (No. 178/UN.16.2/KEP-FK/2023), and it was in accordance with the international guidelines for the use and care of laboratory animals. Standard protocols are followed for treating, experimenting, and disposing of experimental animals.

Twenty-four healthy male Wistar rats (*Rattus norvegicus*) aged between 8 and 12 weeks and weighing 200 and 300 g were used in this investigation. Every rat had limitless amounts of food and liquids and was housed in a cage for 12 h of light and 12 h of darkness each day. The temperature in the cage was set to be between 22°C and 25°C. All rats' body weight and functional index values were measured one day before intervention to ensure they all met the inclusion and exclusion criteria.

Researchers have shown that a single intraperitoneal (i.p.) administration of cisplatin at 15 mg/kg induces toxicity in the cochlea of rats. On day 10, we used an immunohistochemistry test to examine the expression of superoxide dismutase (SOD) in rat cochlear tissue to assess the impact of thymoquinone on cisplatin-induced oxidative stress (Figure 2).

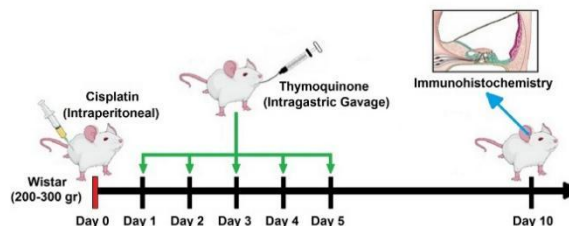


Figure 2: Study Design and Protocol. Male Wistar rats with a body weight of 200–300 gr were used. Intraperitoneal injection of cisplatin (15 mg/kg) was done at the beginning of the study, and thymoquinone was given intragastric gavage from day 1 to day 5. On the day 10, the animals were terminated, and an immunohistochemistry (IHC) examination was carried out on the cochlear tissue to see the expression of superoxide dismutase (SOD).

Experimental intervention

We divided all rats into four groups ($n = 6$ in each group) using simple random sampling, as shown in Table 1. The group that got cisplatin 15 mg/kg (i.p.) and did not get thymoquinone therapy is called the Cis

group; the group that got cisplatin 15 mg/kg (i.p.) plus 25 mg/kg/day thymoquinone intragastric gavage (i.g.) for five days is called the Cis+TQ25 group; the group that got cisplatin 15 mg/kg (i.p.) plus 50 mg/kg/day thymoquinone (i.g.) for five days is called the Cis+TQ50 group; and the group that got a single dose of 0.5 mL normal saline (i.p.) as a placebo without thymoquinone therapy is called the control group. On day 10, SOD expression was tested the expression of superoxide dismutase (SOD) in rat cochlear tissue using an immunohistochemistry examination to evaluate the antioxidant effects of thymoquinone on cisplatin-induced oxidative stress.

Groups	Drug	Dose	Route of Administration
Cis	Cisplatin	15 mg/kg	Intraperitoneal (i.p.)
Cis+TQ25	- Cisplatin	15 mg/kg	Intraperitoneal (i.p.)
	- Thymoquinone	25 mg/kg/day	Intragastric gavage (i.g.)
Cis+TQ50	- Cisplatin	15 mg/kg	Intraperitoneal (i.p.)
	- Thymoquinone	50 mg/kg/day	Intragastric gavage (i.g.)
Control	Normal saline	0.5 mL	Intraperitoneal (i.p.)

Table 1: The study's animal groupings, medication dosages, and administration route.

Samples were divided into four groups ($n = 6$ in each group). Group Cis only received a single dose of cisplatin 15 mg/kg intraperitoneally (i.p.); Group Cis+TQ25 received a single dose of cisplatin 15 mg/kg (i.p.) plus 25 mg/kg/day thymoquinone intragastric gavage (i.g.) for five days; the Cis+TQ50 group received a single dose of 15 mg/kg cisplatin (i.p.) plus 50 mg/kg/day thymoquinone (i.g.) for five days; and the control group was given a single dose of normal saline 0.5 mL (i.p.). Cis, cisplatin; TQ, thymoquinone.

Thymoquinone was procured from Sigma-Aldrich Chemical Co. (Spruce Street, St. Louis, Missouri 63103, USA) with a purity level of 98% and dissolved in corn oil afterward. The administration of the drug was administered via intragastric gavage. Cisplatin was procured from Kalbe Farma Co. (Jendral Suprpto Street, Cempaka Putih, Jakarta 10510, Indonesia) and acquired through a medical prescription.

Immunohistochemistry examination

The cochlea was dissected after the experimental animals had been given intraperitoneally injected doses of ketamine (100 mg/kg) and xylazine (7.5 mg/kg) to induce anesthesia. The cochlear tissue intended for histopathological analysis was immersed in a 10% formalin solution and fixed for 48 hours. The specimens underwent decalcification and were then embedded in paraffin blocks. We partitioned the block into segments, each with a thickness of 4 mm.

We performed immunohistochemical (IHC) testing of trial animal cochlea tissue using primary antibodies against mouse Mn-SOD. The results were read using an Olympus light microscope with a wide field of view, obtained positive expression when a brown color was found in the cytoplasm of epithelial cells, and used to

assess staining intensity of MnSOD expression in the cochlear tissue of experimental animals. Staining intensity was calculated using the ImageJ program (ImageJ 1.49v software, National Institute of Health, Bethesda, USA). By isolating the brown-stained area, the color intensity was reported as an intensity value.

Statistical analysis

We expressed the descriptive data using the mean and standard deviation (SD). We used the Shapiro-Wilk test to assess data normality, Levene's test to assess data homogeneity, and the one-way analysis of variance (ANOVA) test to assess differences among results. In response to identifying a statistically significant difference, we conducted a post hoc analysis. We set the statistical significance level at $p < 0.05$. We analyzed the data using SPSS version 22 (IBM Corporation, Armonk, NY, USA).

Results

SOD expression results using the ImageJ program

The results of the cochlear tissue SOD expression showed that the mean value and SD were 26.64 ± 5.02 in the Cis group, 51.95 ± 2.98 in the Cis+TQ25 group, 56.19 ± 5.43 in the Cis+TQ50 group, and 64.18 ± 5.93 in the control group. There was an increase in SOD expression in the Cis+TQ25 group, the Cis+TQ50 group, and the control group compared to the Cis group, as shown in Table 2.

Group	Mean \pm SD	Min	Max	p^*
Cis	26.64 ± 5.02	11.28	48.59	-
Cis+TQ25	51.95 ± 2.98	39.69	61.72	0.009
Cis+TQ50	56.19 ± 5.43	30.99	69.01	0.002
Control	64.18 ± 5.93	40.41	82.90	0.000

Table 2: Expression of superoxide dismutase (SOD) in cochlear tissues of each group.

There was a decrease in superoxide dismutase (SOD) expression in the Cis group (26.64 ± 5.02) compared to the control group (64.18 ± 5.93). While the Cis+TQ25 group (51.95 ± 2.98) and the Cis+TQ50 group (56.19 ± 5.43) had an increase in SOD expression compared to the Cis group. *Significant if $p < 0.05$. Cis, cisplatin; TQ, thymoquinone.

Overview of cochlear tissue SOD expression from IHC examination

The Cis group found less brown epithelial cell cytoplasm. Brown epithelial cell cytoplasm was found more in the Cis+TQ25 group compared to the Cis group. In the Cis+TQ50 group, there was more brown epithelial cell cytoplasm in the outer hair cells and the organ of Corti supporting cells compared to the Cis+TQ25 group. The control group had the most brown epithelial cell cytoplasm, as shown in Figure 3.

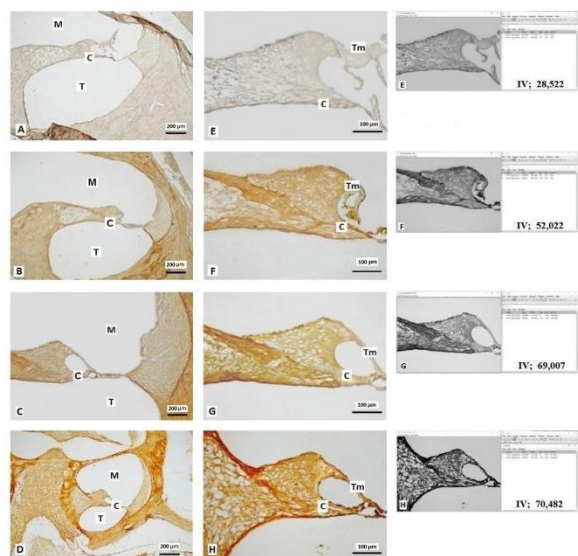


Figure 3: Overview of the immunohistochemical (IHC) examination results of each group to assess superoxide dismutase (SOD) expression, Mn-SOD immunoperoxidase, bar: 100 and 200 μm . MnSOD was expressed in the cytoplasm and extracellular matrix of cochlear tissue as brown staining in immunohistochemistry. The cochlea shows the media scale (M), tympanic scale (T), and organ corti (C). (A, E) cisplatin treatment group; (B, F) cisplatin and thymoquinone 25 mg treatment group; (C, G) cisplatin and thymoquinone 50 mg treatment group; and (D, H) control group. Staining intensity was calculated using the ImageJ program. By isolating the brown stained area, the color intensity was reported as an intensity value. Cisplatin-induced animals (A, E) showed decreased expression of MnSOD in organ corti. Thymoquinone administration showed an increase in cochlear tissue MnSOD expression, especially at the 50 mg thymoquinone dose.

Effects of TQ on oxidative stress induced by cisplatin

The level of oxidative stress in the cochlear tissue is assessed by evaluating and analyzing the cochlear tissue SOD expression. The Saphiro-Wilks test showed that the cochlear tissue SOD expression data were normally distributed ($p > 0.05$), and the Lavene test for cochlear tissue SOD expression showed homogeneous variation ($p = 0.614$).

There were significant differences between the four groups according to an ANOVA test on the cochlear tissue SOD expression results ($p = 0.000$). The Tukey post hoc test revealed that there was a statistically significant disparity between the Cis+TQ25 group, the Cis+TQ50 group, and the control group compared to the Cis group, with $p = 0.009$, $p = 0.002$, and $p = 0.000$, as shown in Figure 4. There was no statistically significant difference in SOD expression found in cochlear tissue between the Cis+TQ25 group, the Cis+TQ50 group, and the control group ($p > 0.05$).

The data revealed that the oxidative stress effect of cisplatin resulted in a decrease in cochlear tissue SOD expression. Administering thymoquinone at 25

mg/kg/day or 50 mg/kg/day for five days of treatment prevents this condition.

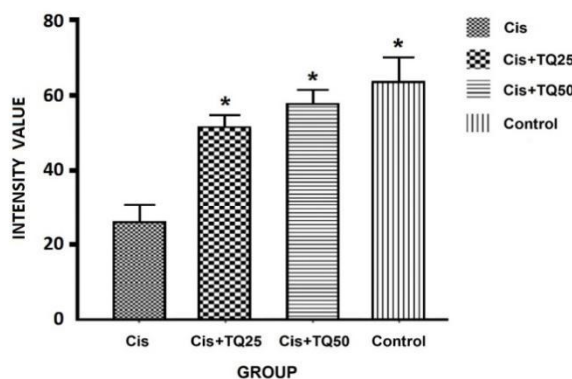


Figure 4: Expression levels of SOD in each group. Data were displayed in each bar as the mean and SD value of each group and analyzed using the Tukey post hoc test with ANOVA. Significant differences were indicated by $*p < 0.01$ vs. the Cis group. Cis, cisplatin; TQ, thymoquinone.

Discussion

Cisplatin causes toxicity in the cochlea (ototoxicity) through intrinsic and extrinsic pathways [13]. This is also consistent with the findings of Kishimoto-Urata et al. [14], who demonstrated that cisplatin elicits oxidative stress within the mitochondria through the intrinsic pathway. Cisplatin not only makes more ROS but also stops the expression of cochlear antioxidant enzymes. Endogenous antioxidants (SOD, CAT, GPx, and GSH-ST) are made by the body to protect itself from oxidative stress [11].

The imbalance between ROS production and antioxidant functions can lead to oxidative stress, which further contributes to apoptosis in the cochlea [1]. The antioxidants reduce the formation of new free radicals by converting free radicals into more stable forms [15]. Cisplatin affects the activity of numerous enzymes, such as catalase, Zn-SOD, Mn-SODA, and Cu, that protect cells from oxidative damage. Research conducted by Kim et al. [16] reported that cisplatin (6 mg/kg/day) administration for ten days will cause nephrotoxicity and a reduction in SOD expression. A similar finding was reported by Kitada [17], who found that kidney Zn-SOD and Mn-SOD expression are decreased by cisplatin toxicity. Previous research has shown that a single intraperitoneal injection of cisplatin at 15 mg/kg can harm test animals' cochleas [5]. Other studies also suggested that single-dose cisplatin administration will decrease SOD activity in the first week of treatment [18]. This study demonstrated that ten days following therapy, a single intraperitoneal injection of 15 mg/kg cisplatin reduced SOD expression in cochlear tissue.

The findings indicate that administration of thymoquinone 25 mg/kg or 50 mg/kg (i.g.) for five days may raise the expression of SOD in cochlear tissue. Pharmacological research has focused on thymoquinone in recent years [19]. Thymoquinone, the primary active ingredient of black cumin (*Nigella sativa*), is a useful antioxidant that can stop ototoxicity caused by cisplatin [7]. Thymoquinone is a potent antioxidant (IC₅₀ = 80.43 µg/mL) that enhances the activity of antioxidant enzymes and eliminates reactive oxygen species, resulting in high total antioxidant status values in the blood [6].

Thymoquinone has a potent ability to scavenge free radicals, particularly hydroxyl and superoxide anions [20]. The administration of thymoquinone orally to adult male Wistar rats increased the levels of SOD, CAT, GPx, and GSH-ST, protecting against cisplatin-induced damage in the liver, heart, and gastrointestinal tract [21]. According to research by Shahid [22], intestinal SOD expression was elevated in response to cisplatin toxicity when thymoquinone was administered orally at a dosage of 1.5 mg/kg/day (i.g.) for 14 days.

In conclusion, thymoquinone mitigates cisplatin-induced oxidative stress by enhancing SOD expression in Wistar rat cochlea.

Acknowledgment

The authors express their gratitude to Prof. Eti Yerizel, Ph.D.; Yan Edward, Ph.D.; Hendriati, Ph.D.; and Ilmiawati, Ph.D., for their invaluable suggestions and contributions that have improved the caliber of this work.

Author Contributions

D.H. and A.E. conceived and designed the study. D.H. and T. performed the experiments. D.H. and S.R. analyzed the data. D.H. wrote the manuscript with input from T. and A.E. All authors read and approved the final version of the manuscript.

Conflict of Interest

The authors declare that there is no conflict of interest regarding the publication of this paper.

References

- Ramkumar V, Mukherjee D, Dhukhwa A, Rybak LP. Oxidative Stress and Inflammation Caused by Cisplatin Ototoxicity. *Antioxidants (Basel)*, (2021); 10(12): 1919.
- Hendriyanto D, Helmi H. Protective role of *Nigella sativa* oil against cisplatin-induced ototoxicity: a literature review. *Journal of the Medical Sciences (Berkala Ilmu Kedokteran)*, (2023); 55(2): 168-178.
- Skarzynska M, Król B, Czajka L. Ototoxicity as a Side-Effect of Drugs: Literature Review. *Journal of Hearing Science*, (2020); 10(2): 9-19.
- Esen E, Ozdogan F, Gorgen SG, Ozel HE, Baser S, et al. Ginkgo biloba and Lycopene are Effective on Cisplatin Induced Ototoxicity?, *The Journal of International Advanced Otolaryngology*, (2018); 14(1): 22-26.
- Lin X, Luo J, Tan J, Yang L, Wang M, et al. Experimental animal models of drug-induced sensorineural hearing loss: A narrative review. *Annals of Translational Medicine*, (2021); 9(17): 1393.
- Abdulbaki H, Al-Deeb MA. Neuroprotective effects of ferulic acid and thymoquinone against deltamethrin-induced neurotoxicity in *Drosophila melanogaster*. *Advancements in Life Sciences*, (2023); 10(2): 289-297.
- Ardiana M, Pikir BS, Santoso A, Hermawan HO, Al-Farabi MJ. Effect of *Nigella sativa* Supplementation on Oxidative Stress and Antioxidant Parameters: A Meta-Analysis of Randomized Controlled Trials. *ScientificWorldJournal*, (2020); 2390706.
- Kokten N, Egilmez OK, Erinc M, Dogan Ekici AI, Serifler S, et al. The Protective Effect of *Nigella sativa* Oil against Experimentally Induced Cisplatin Ototoxicity: An Animal Study. *The Journal of International Advanced Otolaryngology*, (2020); 16(3): 346-352.
- Mekhemar M, Hassan Y, Dörfer C. *Nigella sativa* and thymoquinone: A natural blessing for periodontal therapy. *Antioxidants*, (2020); 9(12): 1260.
- Hendriyanto D, Rahman S, ToFrizal, Elliyantri A. Molecular Targets of Thymoquinone Protection Against Cisplatin-Induced Organ Toxicity: A Literature Review. *International Journal of Chemical and Biochemical Sciences*, (2023); 24(4): 79-86.
- Ighodaro OM, Akinloye OA. First line defence antioxidants-superoxide dismutase (SOD), catalase (CAT) and glutathione peroxidase (GPX): Their fundamental role in the entire antioxidant defence grid. *Alexandria Journal of Medicine*, (2019); 54(4): 287-293.
- Akdemir F, Gozeler M, Yildirim S, Askin S, Dortbudak M, et al. The effect of ferulic acid against cisplatin-induced ototoxicity. *Medicine Science | International Medical Journal*, (2018); 7(3): 528-531.
- Romano A, Capozza MA, Mastrangelo S, Maurizi P, Triarico S, et al. Assessment and Management of Platinum-Related Ototoxicity in Children Treated for Cancer. *Cancers (Basel)*, (2020); 12(5): 1266.
- Kishimoto-Urata M, Urata S, Fujimoto C, Yamasoba T. Role of oxidative stress and antioxidants in acquired inner ear disorders. *Antioxidants*, (2022); 11(8): 1469.
- Sheth S, Mukherjee D, Rybak LP, Ramkumar V. Mechanisms of Cisplatin-Induced Ototoxicity and Otoprotection. *Frontiers in Cellular Neuroscience*, (2017); 11: 338.
- Kim JS, Kim KS, Son JY, Kim HR, Park JH, et al. Protective Effects of *Dendropanax moribifera* against Cisplatin-Induced Nephrotoxicity without Altering Chemotherapeutic Efficacy. *Antioxidants (Basel)*, (2019); 8(8): 256.
- Kitada M, Xu J, Ogura Y, Monno I, Koya D. Manganese Superoxide Dismutase Dysfunction and the Pathogenesis of Kidney Disease. *Frontiers in Physiology*, (2020); 11: 755.
- Sidharta BRA, Purwanto B, Wasita B, Widyaningsih V, Soetrisno S. Single or divided administration of cisplatin can induce inflammation and oxidative stress in male Sprague-Dawley rats. *The Indonesian Biomedical Journal*, (2022); 14(2): 164-171.
- Goyal SN, Prajapati CP, Gore PR, Patil CR, Mahajan UB, et al. Therapeutic Potential and Pharmaceutical Development of Thymoquinone: A Multitargeted Molecule of Natural Origin. *Frontiers in Pharmacology*, (2017); 8: 656.
- Butt MS, Imran M, Imran A, Arshad MS, Saeed F, et al. Therapeutic perspective of thymoquinone: A mechanistic treatise. *Food Science and Nutrition*, (2021); 9(3): 1792-1809.
- Farooq J, Sultana R, Taj T, Asdaq SMB, Alsaman AJ, et al. Insights into the Protective Effects of Thymoquinone

against Toxicities Induced by Chemotherapeutic Agents. *Molecules*, (2021); 27(1): 226.

22. Shahid F, Farooqui Z, Abidi S, Parwez I, Khan F. Oral administration of thymoquinone mitigates the effect of cisplatin on brush border membrane enzymes, energy metabolism and antioxidant system in rat intestine. *Biomedicine and Pharmacotherapy*, (2017); 94: 1111-1120.



This work is licensed under a Creative Commons Attribution-NonCommercial 4.0 International License. To read the copy of this

license please visit: <https://creativecommons.org/licenses/by-nc/4.0/>