



## Full Length Research Article

Advancements in Life Sciences – International Quarterly Journal of Biological Sciences

## ARTICLE INFO

Open Access



Date Received:

16/10/2022;

Date Revised:

27/12/2023;

Date Published Online:

25/02/2024;

# Pathological and Biochemical Methods for Detection of Uranium Pollution in the Diyala-bridge Region, Iraq

Hashim M. Obaid<sup>1\*</sup>, Bushra I. Al. Kaisi<sup>2</sup>**Author's Affiliation:**1. Undersecretary Bureau,  
Ministry of Environment,  
Baghdad - Iraq2. Department of pathology  
and poultry, College of  
Veterinary Medicine,  
University of Baghdad,  
Baghdad - Iraq**Corresponding Author:**

Hashim. M. Obaid

Email:

dr\_hashimalshumay@moen.gov.ig

**How to Cite:**Obaid HM, Kaisi BIA (2024).  
Pathological and Biochemical  
Methods for Detection of  
Uranium Pollution in the  
Diyala-bridge Region, Iraq.  
Adv. Life Sci. 11(1): 263-267.**Keywords:**Uranyl acetate; Granuloma;  
Xenobiotic; Granuloma

## Abstract

**Background:** The present study comprised two distinct experiments. The first experiment involved a field survey conducted in the Diyala Bridge area of Baghdad, Iraq, spanning from December 2021 to May 2022. Soil, milk, and blood samples were collected from locally grazed cattle to ascertain uranium concentrations. In the second experiment, rats were subjected to poisoning with Uranyl acetate. Upon completion of the experiment, samples of liver, kidneys, and blood were collected for histopathological and biochemical analyses.

**Methods:** Twenty-four albino male rats were divided equally and randomly into two groups i.e., control group and intoxicated group. Uranyl acetate was given daily for 120 days by 0.05 mg/kg to the latter group. At the end of the experiment liver and kidney sample were taken for histopathological examination and stained by Masson-trichrome stain.

**Results:** The finding of eosin and hematoxylin stain and biochemical assay for CuZn-SOD U/mg and catalase K/mg protein were showed significantly elevated while liver tissue showed necrosis atrophy atherosclerosis cirrhosis and carcinoma characterized by irregular cell mitotic figure extensive fibrous tissue, tissue kidney presented interstitial hemorrhage and multiple granuloma.

**Conclusion:** Intoxicant by Uranyl acetate showed significant elevating for CuZn-SOD U/mg and catalase K/mg protein, in contrast liver tissue showed necrosis atrophy atherosclerosis cirrhosis and carcinoma, tissue kidney presented interstitial hemorrhage and multiple granulomas.



## Introduction

Pollution has been a global problem for a long time yet just began to be critical after the biotransformation of chemical material like dioxin radioactive pollutant, etc. [1]. Uranium occurs naturally in very small amounts in rocks, soils, water bodies, plants and animals. The history and use of uranium reflect advances in mining, chemistry and physics, and in our understanding of radioactive substances and their potential applications [2]. Earth's crust contains Uranium as a natural component, and it exists naturally in oxidative state [3]. Uranium reach human via food like table salt vegetables cereals which transfer from soil and pollutant soil to plant and human or animals' product mostly (milk, Eggs, meat and fish meat) [4, 5]. Uranium forms are soluble complexes with bicarbonate, citrate or proteins in the plasma when immediately absorbed from tissue and bone [6]. And is directly harmful to the lungs and kidneys [7] and its compounds cause changes in the kidney, lung, liver, nerves, circulation, reproductive system, hemopoietic, DNA deformation and decrease bone development and its known carcinogenic and genotoxic agents [8, 9]. Uranyl nitrate molecular formula  $UO_2(NO_3)_2 \cdot 6H_2O$  with molecular weight 502.13 is a water soluble salt it's a radioactive and oxidizing compound composed of yellow bipyramidal rhombic crystals it easily absorbed by human pulmonary, cutaneous and GIT routes [10&11].

One of the major sites of Uranium pollution in Iraq is AL-Tuwaitha nuclear research site which is located [18] km South west Baghdad and in the Diyala Bridge areas (AL-Arifi and Altaamim Distract) and at Gulf War in 1981 was destroyed and mostly Nowruz reactor in AL-Tuwaitha nuclear research [12].

## Methods

### Sample collection

#### Collection of the soil samples

Randomly 100 soil samples were collected from the lands of Diyala Bridge area like (AL-Tuwaitha, AL-Arifi and Altaamim Distract) Soil samples about 500gm were collected by cutting out the soil (50-100)cm depth then the samples saved in glass containers for laboratory test. Soil samples in laboratory were grinding in mortar and Sieve in fine mesh about 75 Mm then the soil powder after homogenized about 1 gm mixed with 0.2 gm. of methylcellulose then pressed using a piston into a pellet with dimension of 1 cm. diameter and 1.5 mm thickness these pellet to make a pair were covered with CR-39 debtor on both sides [13, 14].

#### Cattle blood collection

Hundred blood samples were collected from both sexes randomly from local grazing cattle in Diyala Bridge area and blood about 10 CC collected from cattle

jugular vein, labeled and saved in heparinized tube in cold box for Uranium detection [13, 14].

### Collection milk sample

Collection from female cattle 100 milk samples were collected daily from the cattle above and area two drops of milk by drying milk and left square piece of CR-39 detector at room temperature for Uranium detection sample save in glass container [13, 14]. Natural Uranium stander samples were prepared according to (IAEA) International Atomic Energy Agency [13, 14]. The experiment analysis above was done in the Ministry of Science and Technology in Baghdad, Iraq.

### Experimental animals

The doses of uranyl acetate (0.05 mg/kg body weight were determined. of uranyl acetate according to [15] and is administration orally. Twenty - four albino male rats aged (120) days and body weight (200-250) gm. were housed in sterilized polypropylene cages (120\*120\*30) Cm<sup>3</sup> in the animal house of the department of Pathology, Collage of Veterinary Medicine, Baghdad University, Iraq, in twelve hours dark light cycle with (21 °C) ambient Celsius degree temperature. All rats were given normal rat pellet and drinking water ad libitum [16]. All animals were under identical management protocol and guide line of Institutional Animal Ethics Committee.

### Intoxication of rats

Twenty - four albino male rates were divided randomly and equally into two groups: -1<sup>st</sup> group (12) animals act as control group (C) received normal rat diet and water ad libitum while 2<sup>end</sup> group (12) albino male rats daily and orally administration ( 0.05 )mg/kg B.W. of Uranyl acetate for 120 days. Uranyl acetate dihydrate  $UO_2(CH_3COO)_2 \cdot 2H_2O$  (Purity99%) was obtained from AccuStandard Inc (New Haven, Connecticut, USA). All rats scarified under ethics protocol under ether anesthesia at 120 days for biochemical and pathological examination.

### Blood collection

Cardiac puncture technique on fasting blood were collected (3 ml) and then blood left (15) minutes to stand and coagulate in refrigerator then for (15) minutes at (500) rpm in centrifuge. Serum was separated and kept at (-20) C<sup>o</sup> till assay.

### Biochemical assay

All below chemicals (purity  $\geq 99\%$ ) were obtain from Sigma chemical Co.(St. Louis, Missouri, USA) and were of analytical grade or of the highest grade available and were done in laboratory of Science and Technology Ministry, Baghdad, Iraq.

- a. **CuZn-SOD (Iu/mg) activity** [17] was measured by inhibition of nitro blue tetrazolium (NBT) reduction due to O<sub>2</sub> generation by the xanthine / xanthine oxidase system and marked by spectrophotometer at (560nm).
- b. **Catalase (CAT) activity (k/mg)** [18]. The enzymatic decomposition of H<sub>2</sub>O<sub>2</sub> followed by decrease in absorbance at (240nm).
- c. **Serum creatinine (mg/dl)** [19].

#### Histopathological change

At days (120) all animals groups were sacrificed and liver and kidney were carefully dissected from abdominal cavity then immediately fixed in 10% neutral buffered formalin for routine histopathological technique [20]. All tissue stained with Masson trichrome stain for fibrous connective tissue detection and eosin and hematoxylin stain.

#### Statistical analysis

All the groups' data were statistically read by SPSS program, version 17 software (2010). Including one way ANOVA for comparisons among groups. P value of less than  $\leq 0.05$  were considered statistically significance, all data were expressed as means  $\pm$  standard error (SE) [21].

## Results

#### Determination of Uranium soil (mg/kg), blood and milk (mg/L)

Uranium concentration in milk ( $0.43 \pm 4.22$ ) mg/L, in blood ( $0.55 \pm 4.22$ ) Mg/L and in soil ( $6.23 \pm 0.54$ ) mg/kg samples were showed significant increased ( $P \leq 0.05$ ) when compare to minimum acceptable Uranium concentration in milk ( $1.2 \pm 0.00$ ) Mg/L, in blood ( $1.8 \pm 0.00$ ) Mg/L and in soil ( $2.8 \pm 0.00$ ) mg/kg

#### Biochemical assay

In current study the level of SOD, CAT and protein in 2<sup>nd</sup> group which administrated (0.05) mg/kg B.W showed significant decreased  $p \leq 0.05$  in CuZn-SOD U/mg protein ( $255.0 \pm 16.2$ ) when compared with control group ( $370.0 \pm 12.0$ ) U/mg protein.

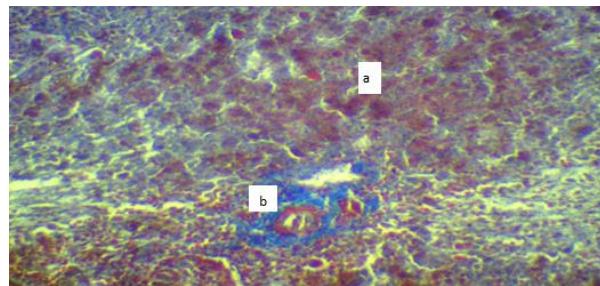
**Catalase k/mg protein** in 2<sup>nd</sup> group decreased significantly ( $p \leq 0.05$ ) ( $4.50 \pm 0.3$ ) when compared with control group ( $8.60 \pm 0.4$ ) k/mg.

**Serum concentration of creatinine (mg/dL)** indicated significant increased  $p \leq 0.05$  in Uranium group when compared to control group.

#### Histopathological Examination

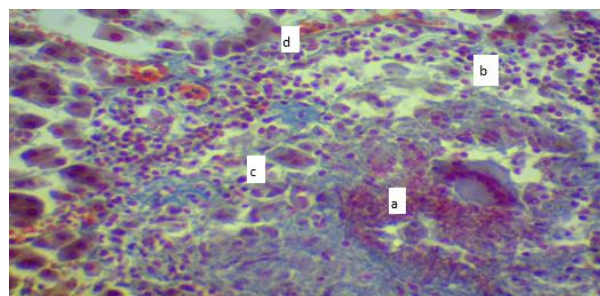
No important histopathological lesions were observed in livers and kidney of 1<sup>st</sup> group (control group), while

2<sup>nd</sup> group at (120) days livers showed hepatic cells atrophied with increased width of sinusoids figure (1).



**Figure 1:** Histopathological lesion of liver (uranyl acetate 0.05mg/kg B.W group) at day (120) showed: a-hepatic cells atrophied b-mononuclear cells aggregation around central vein. X400 (Masson- trichrome stain).

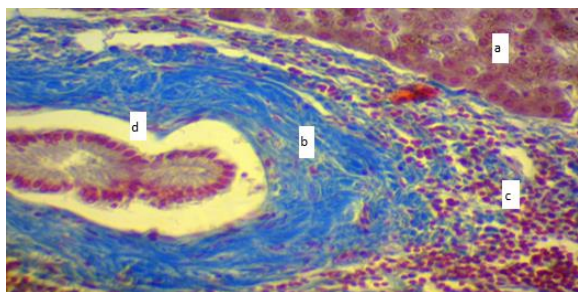
In some areas multiple irregular nodules consist of center of necrosis and hemorrhage surrounded by different types of mononuclear cells mostly macrophages, lymphocytes also surrounded by giant cells and fibrous connective tissue causing damage most layers of hepatocytes with dense blue fibrous connective tissue figure(2).



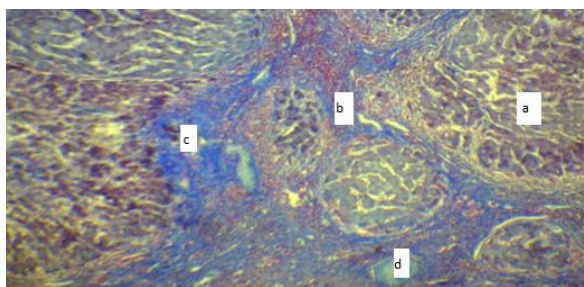
**Figure 2:** Histopathological lesion of liver (uranyl acetate 0.05mg/kg B.W group) at day (120) showed: a-irregular nodules of necrosis and hemorrhage b-different types of mononuclear cells c- giant cell d-fibrous connective tissue X400 (Masson-trichrome stain).

Granulomatous areas showed increase in the fibrous connective tissue with blue coloration, other liver cells consist a huge amount of leukocytes mostly eosinophil's and lymphocytes, collapsed of all arteries with sever atherosclerosis figure (3). Liver cirrhosis characterized by hyperplastic parenchymal nodules separated by fibrous bands with distortion of the normal liver architecture with moderate infiltration of mononuclear cells with newly bile duct fig(4). Kidney section in 2<sup>nd</sup> group presented sever acute cellular swelling, sever interstitial hemorrhagic with granuloma formation consist of (necrotic center surrounded by foreign body giant cells) Fig (5).

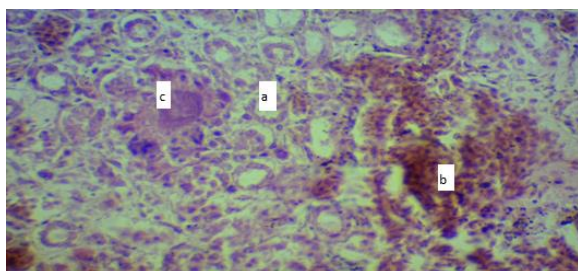




**Figure 3:** Histopathological lesion of liver (uranyl acetate 0.05mg/kg B.W group) at day (120) showed: a-liver necrosis b-thick fibrous connective tissue c-extensive leukocytes mostly eosinophil and lymphocytes d-atherosclerosis X400 (Masson-trichrome stain).



**Figure 4:** Histopathological lesion of liver (uranyl acetate 0.05mg/kg B.W group) at day (120) showed a-hyperplastic parenchymal nodules b-thick fibrous tissue c-mononuclear cell infiltration d-newly bile duct X400 (Masson-trichrome stain).



**Figure 5:** Histopathological lesion of kidney (uranyl acetate 0.05mg/kg B.W group) at day (120) showed: a-acute cellular swelling b-sever interstitial hemorrhage c- foreign body giant cell granuloma X 200 (H&E stain).

## Discussion

Our results showed significant increase in Uranium concentration in soil, milk and blood of cattle when compared to minimum accepted uranium concentration. Uranium accumulation in Diyala bridge area like (AL-Tuwaitha), AL-Arifi and Altaamim District due to war (1981) and terrorism [22] also gulf war resulting in presence radioactive of Uranium in soil surface and the invade the deeper layer of ground [23]. The bioaccumulation of soil uranium in the above areas that act as potentially long-term source of food contamination because Uranium half-life( $4.5 \times 10^9$ ) years [24], when ingested randomly by cattle which grazing in these contaminated areas accumulate in

milk, blood, meat and different tissue like kidney, bone, brain and mostly liver [25]. The current study showed significant decreased in CuZn-SOD and catalase with in creatinine which induction of oxidative stress in tissue and may be due to lipid peroxidation causing increase cell fluidity and cell death due to oxidative stress and free radical [26]. Liver is often show by toxic effects of xenobiotic due to its ability to accumulate xenobiotic by active transport [27]. Uranium has ability to accumulate in hepatocytes and cause toxicity [28 and 29], by induce oxidative stress in mitochondria or lysosome [30]. In rats hepatocytes uranium is potential oxidative marker including reactive oxygen species (ROS) formation and generation excessive (ROS) in liver. Liver cirrhosis is the global lesion occurs due to liver damage from toxin which causes losses of liver function in human and animals [31]. Formation of pseudolobules without central vein surrounding by fibrous connective tissue (cirrhosis) to maintain regeneration of hepatocyte due to Uranium mutagenicity effect of uranium genetic mutation causing liver carcinoma and such effects can include genetic mutations generation of (ROS) lead to liver carcinoma [32]. Chronic toxicity due to Uranium exposure experimental due to excreted via kidneys especially in proximal convoluted tubules causing renal tubular epithelial degeneration, necrosis with inflammatory cells infiltration and increased serum creatinine due to brush cell injury and alteration in cells and lysosome membrane with injury to mitochondria leading to impaired energy and altered calcium ion hemostasis, uranium induction cellular oxidative stress [33], by increased lipid peroxidation and depletion of antioxidant enzyme[34], causing vacuolation mesangial and epithelial cells of glomeruli, dilated renal tubules, interstitial fibrosis with mononuclear cells infiltration[35], with fibroblastic proliferative by produce protein like collagen I, IV and fibronectin-growth- factor  $\beta$  (TGF- $\beta$ ) and platelet-derived growth factor (PDGF) [36].

## Author Contributions

Hashim M. Obaid: Research article, funding the acquisition and experiment design.

Bushra. I. al. Kaisi: Preparing materials, explain the finding, statistical analysis, review and editing.

## Conflict of Interest

The authors declare that there is no conflict of interest.

## References

1. Humadi A, Sabeeh I, Al-Kaisei I, Al-Ezzy I. Toxicopathological and Biochemical impacts of 2, 3, 7, 8 Tetrachlorodibenzo-P-Dioxin (TCDD) on liver of Albino male rats. *International Journal of Pharmaceutical Research*, (2021); 1(13): 2536-2545

2. Balaram A, Rani A, Rathore D. Uranium in groundwater in parts of India and world: A comprehensive review of sources, impact to the environment and human health, analytical techniques, and mitigation technologies. *Geosystems and Geoenvironment*, (2022); 1(2):100043
3. Brugge D, Jamie L, deLemos L, Beth O. Exposure pathways and health effects associated with chemical and radiological toxicity of natural uranium: a review. *Reviews on environmental health*, (2005); 20(3): 177-194.
4. AL-Tameemi H. Radiological and chemical hazards of public exposure to uranium-235 at Al-Twaita nuclear research site. *Iraqi Journal Biotechnol*, (2010); 9(2): 226-38.
5. Priest D. Toxicity of depleted uranium. *The Lancet*, (2001); 357(9252): 244-246.
6. Cooper R, Stradling N, Smith H. The behaviour of uranium-235 oxide and uranyl-235 nitrate in rats. *International Journal of Radiation Biology and Related Studies in Physics, Chemistry and Medicine* (1982); 41(4): 421-433.
7. Patocka J. Human health and environmental uranium. *Military Medical Science Letters*, (2014); 85.3: 120-131.
8. Craft S, Abu-Qare W, Flaherty M, Garofolo C, Rincavage L, Abou-Donia B. Depleted and natural uranium: chemistry and toxicological effect. *Journal of Toxicology and Environmental Health*, (2004); 7(4) : 297\_317
9. Hartmann M, Frederick A, Halil A. Overview of toxicity data and risk assessment methods for evaluating the chemical effects of depleted uranium compounds. *Human and Ecological Risk Assessment*, (2000); 6.5: 851-874.
10. Kozlova D, Matyukha V, Dedov N. Mechanism and kinetics of thermal decomposition of uranyl nitrate hexahydrate under the nonisothermal conditions. *Radiochemistry*, (2007); 49.2: 130-134.
11. Heffernan E, Lodwick C, Spitz H, Neton J, Soldano M. Solubility of airborne uranium compounds at the Fernald Environmental Management Project. *Health Physics*, (2001); 80(3): 255-262.
12. Al-Shammari M. Environmental pollutions associated to conflicts in Iraq and related health problems. *Reviews on environmental health*, (2016); 31(2): 245-250.
13. Aziz. A, Majed M, & Tawfiq F. Evaluation of Uranium Concentration in the Blood of Cancer Patients in Salah Al-Din Governorate. *Tikrit Journal of Pure Science*, (2021); 26(2): 94-97.
14. Hassan A. Determination of uranium in fishes samples from selected regions in Iraq using neutron activation technique for nuclear track detectors. *AL-Qadisiyah Journal of pure Science*, (2017); 22(2): 47-59.
15. Domingo L, Ortega A, Paternain L, Corbella J. Evaluation of the perinatal and postnatal effects of uranium in mice upon oral administration. *Archives of Environmental Health: An International Journal*, (1989); 44(6): 395-398.
16. Humadi A, Bushra I, Taghreed H. Acrylonitrile testicular seminoma in beagle male dogs (Pathological and Hormonal assay). *Plant Archives*, (2020); 20(1): 1903-1909
17. Ciftci O, Sadettin T, Ahmet G. Protective effect of curcumin on immune system and body weight gain on rats intoxicated with 2, 3, 7, 8-Tetrachlorodibenzo-p-dioxin (TCDD). *Immunopharmacology and Immunotoxicology*, (2010); 32(1): 99-104.
18. Damiano S, Longobardi C, Andretta E, Prisco F, Piegari G, Squillacioti C, Ciarcia R. Antioxidative effects of curcumin on the hepatotoxicity induced by Ochratoxin A in rats. *Antioxidants*, (2021); 10(1): 125.
19. Henry J, Cannon D, Winkelman W. *Clinical chemistry. Principles and techniques*, 2nd Edition, Harper and Row, Hagerstown, (1974); 525-527
20. Humadi A, Bushra I, Marah S. Pathological and hormonal effects of 2, 3, 7, 8- Tetrachlorodibenzo-p-dioxin (TCDD) Versus antioxidant activity of Curcumin in Sprague dawley male rats. *Veterinary Practitioner*, (2020); 21(2): 439-443
21. Duncan B. "Multiple range and multiple F tests." *Biometrics*, (1955); 11(1): 1-42.
22. Brown J. Reconstructing the environment in Iraq. *Environmental health perspectives*, (2004); 112(8): A464-A464.
23. Katsoyiannis A, Hug J, Ammann A, Zikoudi A, Hatziliontos C. Arsenic speciation and uranium concentrations in drinking water supply wells in Northern Greece: correlations with redox indicative parameters and implications for groundwater treatment." *Science of the Total Environment*, (2007); 383(1-3): 128-140.
24. Claiborne P. *Handbook of methods for oxygen radical research*. Florida: CRC Press, Boca Raton, (1985); 283-284.
25. Jeambrun M, Pourcelot L, Mercat C, Boulet B, Loyer J, Cagnat X, Gauthier-Lafaye F. Study on transfers of uranium, thorium and decay products from grain, water and soil to chicken meat and egg contents. *Journal of Environmental Monitoring*, (2012); 14(8): 2170-2180.
26. Dublineau I, Grison S, Baudelin C, Dudoignon N, Souidi M, Marquette C, Gourmelon P. Absorption of uranium through the entire gastrointestinal tract of the rat. *International journal of radiation biology*, (2005); 81(6): 473-482.
27. Racine R, Gueguen Y, Gourmelon P, Veyssièrè G, Souidi M. Modifications of the expression of genes involved in cerebral cholesterol metabolism in the rat following chronic ingestion of depleted uranium. *Journal of molecular neuroscience*, (2009); 38(2): 159-165.
28. Mohammed A, Eyad A. The biochemical and histological effects of uranyl acetate in male New Zealand rabbits. *Al-Qadisiyah Journal of Veterinary Medicine Sciences*, (2015); 14(2): 25-30
29. Arfsten P, Kenneth R, Glenn R. Review of the effects of uranium and depleted uranium exposure on reproduction and fetal development. *Toxicology and industrial health*, (2001); 17(5-10): 180-191.
30. Fukuda S, Ikeda M, Nakamura M, Yan X, Xie Y. Acute toxicity of subcutaneously administered depleted uranium and the effects of CBMIDA in the simulated wounds of rats. *Health physics*, (2009); 96(4): 483-492.
31. Asrani K, Larson J, Yawn B, Therneau M, Kim R. Underestimation of liver-related mortality in the United States. *Gastroenterology*, (2013); 145(2): 375-382.
32. Wanless R, Eisuke N, Morris S. Regression of human cirrhosis: morphologic features and the genesis of incomplete septal cirrhosis. *Archives of pathology & laboratory medicine*, (2000); 124(11): 1599-1607.
33. Shim S, Park H, Ahn J, Han L, Jin R, Li H, Shim K. Testosterone-independent down-regulation of Oct2 in the kidney medulla from a uranyl nitrate-induced rat model of acute renal failure: Effects on distribution of a model organic cation, tetraethylammonium. *Journal of pharmaceutical sciences*, (2009); 98(2): 739-747.
34. Sun F, Fujigaki Y, Fujimoto T, Goto T, Yonemura K, Hishida A. Relation of distal nephron changes to proximal tubular damage in uranyl acetate-induced acute renal failure in rats. *American journal of nephrology*, (2002); 5-6(22): 405-416.
35. Hamid J. Uranyl nitrate induce histological changes in the kidney. *International Journal of Engineering and Technology*, (2012); 12(4): 9-13.
36. Banday A, Priyamvada S, Farooq N, Yusufi K, Khan F. Effect of uranyl nitrate on enzymes of carbohydrate metabolism and brush border membrane in different kidney tissues. *Food and chemical toxicology*, (2008); 46(6): 2080-2088.



This work is licensed under a Creative Commons Attribution-NonCommercial 4.0 International License. To read the copy of this license please visit: <https://creativecommons.org/licenses/by-nc/4.0/>