



Full Length Research Article

Advancements in Life Sciences – International Quarterly Journal of Biological Sciences

ARTICLE INFO

Open Access



Date Received:
28/07/2023;
Date Revised:
30/08/2023;
Date Published Online:
31/12/2023;

N-cadherin protein-immuno-histochemical expression of the blood-testis barrier in male mice fed with diet minced with insecticide Bifenthrin

Author's Affiliation:
Dept. human anatomy, College
of Medicine, Al-Nahrain
University - Iraq

Mohammed Fawzi Faisal*, Haider Abdulrasool Jaafar

Corresponding Author:
Mohammed Fawzi Faisal
Email:
mohammadfawzi997@gmail.com

How to Cite:
Faisal MF, Jaafar HA (2023).
N-cadherin protein-immuno-
histochemical expression of
the blood-testis barrier in
male mice fed with diet
minced with insecticide
Bifenthrin. *Adv. Life Sci.*
10(4): 593-599.

Keywords:
Bifenthrin insecticides; N-
cadherin; Spermatogenesis;
Sertoli cells; Leydig cells;
Seminiferous tubule; Basal
lamina; Blood-testis barrier

Abstract

Background: Testis play role as endocrine organ by regulate and synthesis of hormones, and genital role as germ sells production (spermatogenesis) for reproduction process. The Sertoli cells in the seminiferous tubule with basal lamina and endothelium of vesicles, form a special structure called blood-testis-barrier (BTB) with the protection function and specific properties that similar to blood tissue barriers of other body organs.

Methods: Forty male healthy Swiss albino mice weighing 24-30 g will be kept in 2 groups (20 for each) in the labs of Al-Nahrain University College of medicine for 6 weeks from 1 December 2022_15 Jan 2023. Regular rodent food and water will be provided and Grouping as: Group A food minced with concentration of 400mg/kg of Bifenthrin insecticides and Group B have normal food.

Results: The histological study showed partial depletion testis cells in all mice testes with non-significant decrease in interstitial space that has Leydig cells between seminiferous tubule (ST) in testis of male mice that were fed with Bifenthrin diet. There were less cadherin expression in the BTB indicating that the Bifenthrin has stressful stimulus to potentiate apoptosis in the genital and somatic (Sertoli) cells of the testis that eventually impact the cadherin protein. The Bifenthrin has as stimulant chemical factor for more apoptosis in the ST cells death with subsequently testicular atrophy and subsequently infertility. The Bifenthrin treated male mice shows significant diminish positive values of N-cadherin expression that appear as less brown coloration of immunohistochemical biomarker expression of N-cadherin in the ST cells of the testis that was best evaluated by applying Aperio software program.

Conclusions: The N-cadherin protein has pivotal role in regulation the adhesiveness of the germinative-epithelial cells in ST of the testis. The Bifenthrin insecticides as an endocrine disrupter material has great effects on spermatogenesis and tissue damage.



Introduction

The blood-testis barrier is another example of “one of the tightest junctions” in the mammalian body. Located near the base of the seminiferous tubule, where it divides the epithelium into 2 distinct compartments, basal and adluminal [1]. Tight junctions, ectoplasmic specializations, desmosomes create the blood-testis barrier, and gap junctions that are present between Sertoli cells, these structures, effectively exclude immune system cells and antibodies or other chemicals from entering the germ cells in seminiferous tubules that undergo meiotic division and haploids [2]. Sertoli cells are large pyramidal-shaped cells, and the base resides on the basal lamina of the. However, that Sertoli cells are essential in spermatogenesis originates from general experimental observations [3]. Spermatogenesis depends on the availability of interstitial-Leydig cells to create testosterone hormone by the effect of luteinizing hormone. These interstitial cells have a play at the time of spermatogonia differentiation under the effect of human chorionic gonadotropin in the placenta that ends in the secretion of androgen in the gestational period. These interstitial cells of Leydig arise from the proliferation of mesenchyme stem cells by the effect of LH at the pubertal period. There are certain Influences tat produced by supporting-Sertoli cells and myoid cells of ST that are essential for interstitial cell development and steroidogenesis [4].

Mouse testicle histology- blood-testis barrier (BTB)

The tight junctions in the testis present in co-function with ectoplasmic specializations. The gap junctions and adherent junctions can be found between the areas of plasma membrane which also have tight junctions in the basal ectoplasmic specializations [5]. The BTB has Main role in maintaining male productiveness (fertility). The integrity of tight junctions provides restricted permeability of this barrier. The interruption in the BTB and tight junctions may reveal inadequate spermatogenesis, which is one of the mechanisms behind sperm deletion (azoospermia) [6]. The BTB divides the ST epithelial cell into 2 diverse compartments, basal near basal lamina and adluminal near lumen of ST, which is essential for process of spermatogenesis. So the isolation of spermatocytes which present in adluminal area from interaction with immune system and also from local immune suppression, is the main function of the BTB is so as to provide an immune-privileged microenvironment for the meiosis completion [7].

Spermatogenesis

A sequential sequence of cellular eventual that lead the production of well-developed spermatozoa in process

of Spermatogenesis it takes 48–53 days in the rodent [8]. In the presence of LH, interstitial-Leydig cells in the interstitial space, secrete androgen which help the viability of the testis BTB, spermatogenesis, and fertility [9], And it promotes both supporting and germinative cells desmosomal adhesion get-together than get-away from each other [10].

N-cadherin

The viability of plasticity epithelium cells and are formed by a family of proteins known as desmosomal cadherins, and due to disruption of intercellular adhesion that is pivotal role in the cancer activation. Desmosomal-Cadherins are proteins with Ca dependent trans-membrane that are related to actin-microfilament of certain proteins in the cytoplasm. Disorder in the intercellular adhesional proteins in cancer disastrous effect in metastasis and invasiveness of cancer to various region of the body [11]. The spermatogenesis is the process by which non-mature male germinative cells divide, have meiotic division into specialized and differentiated sperm. Both androgen (by its receptor) with FSH is activates the maximum spermatogenesis [12].

Chemical materials and Chemotherapy that induced-infertility

Certain researchers have reported that chemotherapy is used for child with cancer leading to infertile children. Before pubertal time the-spermatogonia in the testis of child, although they unable to make spermatozoa. Cisplatin had significantly decreased in the germ cell marker gene expression, involving both undifferentiated with differentiated, according to doses that applied with high doses of cisplatin drug that show marked death of germ cells [11]. Further researchers had been found that testis damage can affect the germinative cells in spermatogenesis of the testis that are disturbed by application of cyclo-phosphamide chemotherapy. Cell death in cisplatin therapy due to reactive oxygen species (ROS) excessive production. The testicular ROS production on smooth endoplasmic reticulum by the chemotherapy cisplatin that induces long lasting testicular damage [11].

Insecticides

Lead arsenate as natural and inorganic insecticides was the only insecticides had been applied, till they were replaced by newly active synthetizing materials in late 1940s. The organochlorine insecticides that followed by the organophosphate, carbamates, pyrethroid, phenyl pyrazoles, with recently, the neonicotinoids that had been applied in agricultural field [13]. The different histological features and functions of each type of ST that are liable to certain effector materials, like dysregulation hormones and oxidation reduction

effects [14, 15]. The insecticides can act as obesogens with infertility in male were closely related [16].

Insecticides effect on Leydig cells

In male rodent the experimental studies with treatment with dimethoate, insecticide, and reveals endocrine disruptor in rats that has been affected interstitial cells. the decrease in the blood levels of androgen, with increase in blood follicular stimulating hormone and luteinizing hormone levels also decrease in the size of interstitial cells due to normal feedback negatively in the Hypothalamic pituitary testis axis [17].

Sertoli cells

The BTB integrity alterations, with inactive sperm motility that by the stress of oxidation reduction chemistry of methyl parathion, insecticide that invading the intercellular junctions' complexes of the BTB [18]. Certain researchers reported that pesticide of bifenthrin related with malfunction of powerhouse region in the cytoplasm of supporting-Sertoli mitochondria which is pyrethroid family of insecticides [19]. Moreover, a study on cypermethrin reveals that there was a decrease in functional activity of supporting cells of mice, which is caused by its androgen antagonist activity as it is a synthetic pyrethroid insecticides. The cypermethrin distress that influence the ST supporting cells to be activated by androgen receptor stimulation [20]. Moreover, researchers revealed that there were marked diminishing in the stem - spermatogonia cells of ST, they found that there was necrotic tissue in ST in testicle of rats that treated with an organophosphorus compound -chlorpyrifos and this study concluded that there was decrease in the testicular antioxidant system. They found that this chemical has disrupting the endocrinal aspect of the testis in the affecting levels of testosterone due to diminishing in the interstitial cells of ST in the testis [21]. Neoplastic changes in the male reproductive tract and blood-testis barrier: By applying cadmium it lead to well-marked sperm loss due to toxic effect on supporting-Sertoli cells in seminiferous tubule, and their BTB that are structurally damaged. So it represents main risk factor for male fertility [22].

Methods

Ethical agreement

The College of medicine /Al-Nahrain University gave approval for this study (2023/12/27), (No: 20220909), (IRB/78).

Samples of experimental animals

Forty male healthy Swiss albino mice weighing 24-30 g will be prepared. These male mice were housed in 2 groups in the animal care facility of AlNahrain University College of medicine in a 12-hour light-dark

cycle for control group. Grouping as follow:-Group A: 20 male mice feed on food minced with concentration of 400mg/kg of bifenthrin (pyrethroid) insecticides for 6 weeks. Group B: 20 male mice feed on healthy food for 6 weeks from 1 December 2022_15 Jan 2023. The testis of male mice were harvested as whole mass Blocks from the pelvic region then coronal section of the testis of male mice were done.

Tissue processing

The testis of male mice was immersed in 10% formalin for at least 24 hours. A 0.5-1.0 cm block of testis was cut, placed into serially dehydrated and cleared solutions sectioned for H & E. and immunohistochemical assessments had be done using anti- N- cadherin marker kit by 5 µm thick sections for immunostaining. N- Cadherin marker had been purchased from ABCAM.

Experimental setting

This study take place in labs of anatomy Department, Al-Nahrian University. The timeline of experimental work was start from November 2022 till June, 2023.

Animal dissection

Animals scarified by inhalation of chloroform by soaking it in cotton piece in glass chamber about 4 min. after that, the animals were set on anatomical stage on fixed dorsal position on dissecting table. We observed the behavior of the animals during the experiment. The weights of animals were measured before and after exposure to the insecticide. Pre-dissection: Fixative solution as 10% formalin solution was injected intra-cardiac through left ventricle into aorta (so that tissues fixation was done by modified perfusion method) as done by certain researchers. Then the specimens of testis tissue were preserved in 10% formalin for 24hours in order to obtain paraffin tissue blocks. The specimens were histologically prepared for paraffin section as follows Fixation, dehydration, clearing, impregnation, embedding, and sectioning de-waxing, staining and mounting. The paraffin of the testis sections for each group were stained with Hematoxylin (Harris Alum -hematoxylin) and Eosin stain for general histological tissue examination.

Immunohistochemical reaction

Anti N-cadherin polyclonal (IgM) antibody was used, it is specific for the N-cadherin protein in mouse that acts as junctional complexes protein. The procedure was done according to that was received from the manufactured company Sigma Aldrich-Germany and the staining kit received from Abcam United Kingdom.

Morphometry

by ImageJ analysis is done using the software ImageJ (Java based image processing program developed at the

National Institutes of Health, USA) version 1.47p that has been installed in personal computer. ImageJ is the key in the morphometric studies that different procedures and process can be performed to read certain image formats like JPEG, GIF, BMP, and TIFF [23].

Immunohistochemical reaction assessment (Aperio Algorithm Program)

Aperio Image Scope V12 positive pixel algorithms for count used for measurement of quantity of brown coloration for detecting certain protein markers as cadherin, P73, laminin, integrin and CD326 etc. in a tissue section that had been applied by certain researchers for similar studies [24]. There are weak+, + and strong+ that were detected by the program, which have sets of input default parameters that have formed for measurement of DAB-brown coloration of in the three intensity varieties degrees which are, the algorithm was used to an image. The degree of positivity measured with Aperio Image Scope program showed 4 colors: The strong positive appeared as red color. The positive appeared as orange color. The weak positive appeared as yellow color. The negative appeared as blue color.

Statistical analysis of the data

The analysis of the present study was performed by statistical package of social sciences (SPSS) program V22. The positive pixels of immunohistochemical reactivity of N-cadherin protein marker expression in Sertoli cells of the testis among the studied groups. A p value less than 0.05 was considered statistically significant.

Results

Effect of Bifenthrin treated animals on histological and morphometric changes in the testis of male mice

The result show morphometric and histological changes in the testis of male mice wrinkled architecture and blebbed appearance to the outline of testis tunica albuginea. (Figure 1).

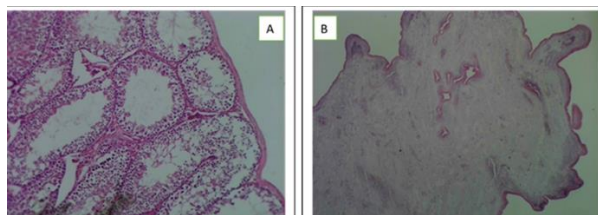


Figure 1: A: Cross section of testis of non-treated animal, B: Cross section of testis of treated animal. (stained with H&E stain in 10X).

Thickness of seminiferous tubules (ST) in microns

The seminiferous tubules of Bifenthrin treated animal's shows decrease in diameters and thickness of germinative epithelium. The thickness of seminiferous tubules (ST) of animals show significant value (p values < 0.001) before and after exposure to Bifenthrin diet that recorded with mean and stander deviation of treated was (77.11 ± 12.07) and untreated was (247.82 ± 28.96) respectively. There revealed that the Bifenthrin diet has effects on decrease in diameter thickness of seminiferous tubules (ST) of experimental mice. (Table 1)

Thickness of epithelium seminiferous tubules (ST) in microns

The thickness of epithelium of seminiferous tubules (ST) of animals show significant value (p values < 0.05) before and after exposure to Bifenthrin diet that recorded with mean and standard deviation of untreated group was (60.47 ± 4.41) and treated group was (25.64 ± 7.77) , respectively.

There revealed that the Bifenthrin diet has effects on decrease in epithelium thickness of seminiferous tubules (ST) of experimental mice (Table 1).

The germinative epithelium has low cellularity of both Sertoli cells and spermatogonia that seen near the basal layer seminiferous tubules in comparison to other non-treated group (Figure 2). The germinative epithelium at the luminal surface reveals low cellularity of spermatid cells that are seen release as in process of spermatogenesis in comparison to other non-treated group (Figure 2).

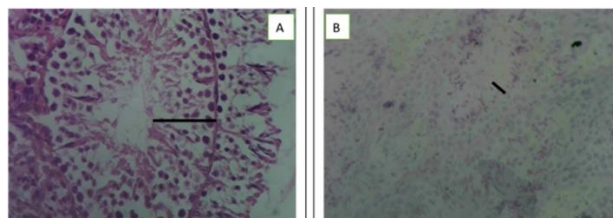


Figure 2: A: Cross-section of testis of non-treated animal, B: Cross-section of testis of treated animal. (Stained with H&E stain in 40X).

Interstitial space of seminiferous tubules (ST)

The interstitial space thickness of seminiferous tubules (ST) of animals show non-significant value (p values > 0.05) before and after exposure to Bifenthrin diet that record with mean and standard deviation of treated group was (39.63 ± 9.82) and untreated group was (32.32 ± 12.99) respectively. There revealed that the Bifenthrin diet has no effects on increase in interstitial space of seminiferous tubules (ST) of experimental mice (Table 1).

Effect of Bifenthrin treated animals on the immunohistochemical expression of N-cadherin of blood-testis barrier in the testis of mice by using Aperio program

The expression of N-cadherin in the seminiferous tubules of Bifenthrin-treated animals showed significantly lower positive values of brown coloration DAB stain of immunohistochemical staining method than that of the non-treated group. (Figure 3)




Figure 3: A: Cross-section of testis of non-treated mice, B: Cross-section of treated mice (IHC staining) (10X). *ST (seminiferous tubule), *IS (interstitial space).

The expression of N-cadherin strong positive in Aperio program show significant value (p values < 0.001) before and after exposure to Bifenthrin diet that mean and standard deviation of treated group was (60353.1 ± 25988.9) and untreated group was (120595.1 ± 35498.1), respectively. (Figure 4), (Table 1).




Figure 4: A: non-treated animal, B: treated animal. (Reveals expression of N-cadherin strong positive in Aperio program for analysis of brown coloration of DAB 40X).

Parameter	Tested groups	Mean Um	Std. Deviation	P value
thickness of seminiferous tubules (ST) in microns	Untreated	247.82	±28.96	0.001*
	Treated	77.11	±12.07	
epithelial thickness of seminiferous tubules (ST) in microns	Untreated	60.47	±4.41	0.05*
	Treated	25.64	±7.77	
interstitial space thickness in between seminiferous tubules (ST) in microns	Untreated	39.63	±9.82	0.05*
	Treated	32.32	±12.99	
immunohistochemical expression of N-cadherin of blood-testis barrier in the testis of mice by using Aperio program	Untreated	60353.3	±25988.9	0.001*
	Treated	120595	±35498.1	

* P-value that is less than 0.05 is considered statistically significant while if it is less than 0.01 is viewed as highly statistically significant.

Table 1: The statistical parameters of animals' groups before and after exposure to Bifenthrin diet.

Regarding the drug safety, only one patient in the G-CSF group developed a mild fever with the first dose of G-CSF, which was treated with a paracetamol tablet (500 mg/8 hours) orally for three days, and no fever developed with subsequent doses of G-CSF in the same patient.

Discussion

Effects of Bifenthrin treated animals as an obesogenic on body Weight in mice

The present study reveals that Bifenthrin treated group animals were developed passive increment in body weight as compare to non-treated -group mice and this approve with other researchers who studied on insecticides-treated animals that recorded the chemical remains in the environment are measured to be significant factors that cause fatness [25].

Effects of Bifenthrin treated animals on awareness and aggressiveness behavior in mice

The present study reveals that Bifenthrin treated group animals were developed passive attitude with calmness behavior as compare to non-treated -group mice and this approve with other researchers who expose studied insecticides related psychological health in Thai-land that were not well recognized. They also found that these agriculturalists having formerly reported insecticides harming symptoms was related to psychological disorder, the findings provided evidence of insecticides exposure posing a risk to farmers' mental health, mainly long term and high-intensity exposure [26]. Moreover, others found that exposure to organophosphates had impacting psychological distress; mental health also environmental or occupational exposures can disturb neurochemistry and, hence, predispose to psychological distress [27, 28].

The effect of Bifenthrin treated animals on induction the programmed cell death (apoptosis) and the cells viability of blood-testis barrier in the testis of mice

This present study concluded that there were signs of programmed cell death (apoptosis) as pyknosis, foamy cytoplasm, blebbed cell membrane involve the ST cells and less cadherin expression in the barrier (BTB) indicate that mean more apoptosis cells were seen that mean cadherin has vital role in spermatogonia and supporting (Sertoli) cells growth and development which are essential for process of spermatogenesis with differentiated active functioning cells with less apoptosis that act as a pro-survival factor. This is reverse for Bifenthrin pesticide as stimulant chemical factor for apoptosis and ST cells death with subsequently testicular atrophy and subsequently infertility. This was agreed with other examiners who found that light effect of on the activity of the

developing follicles in ovaries, or germinative epithelium of ST of testis or inner layer of eyeball, retina in mice [29]. Moreover, other authors found that cisplatin has effect in whole cells of the body that by the oxidative stress induction which damaged DNA and death in triggering cell. Cisplatin enhances chronic testis damage by production of reactive oxygen species in males gonad cells so that treatment with cisplatin increased reactive oxygen species in supporting-Sertoli cells of testis of mice. The organ culture had been studied so as to assess the chemicals toxicity that lead to endocrine dysfunction of the testicle by performing analysis of these chemicals and medical drugs on system of reproductively and testicle development was done by apply the cells culturing method of these animals [11].

The toxic effect of Bifenthrin treated animals on genital and somatic (Sertoli) cells in the testis of mice:

The present study will highlight further research that should be expanded in future studies about increment in infertility incidence, also recommending for importance of control the insecticides that dysfunction and disruption of endocrine system in body of the contaminated food and this agree with reporters who found there are insecticides involve in certain impact on the reproductivity system that cause or lead to male infertile by in vivo and in vitro studies. They concluded that the germ cell differentiation was taken place by effects of the metabolites and molecular features of insecticides on germinative with somatic tissues [13]. Further studies found the cisplatin-treated mice revealed defect with low value in expression of the germ-cell specific biomarkers that were studied by applying immunohistochemistry. They concluded that ST epithelial cells consisting of supporting cells, which had supportive activity for germ cell growth so that the exposure to cisplatin had great effects on supporting cell existence. The supporting cell biomarkers expression were largely decreased according to blood concentration of cisplatin. The present study reveals a non-significant decrease in interstitial space that has interstitial (Leydig) cells between ST. these cells synthesized and secrete steroid hormones by assistance of Steroidogenic enzymes which produce androgen that are required for spermatogenesis and potentiate the other reproductive functions [11]. This present study concluded that bifenthrin is stressful stimulus that potentiates apoptosis of genital and somatic (Sertoli) cells in the testis.

Effect of Bifenthrin treated animals on the immunohistochemical expression of N-cadherin of blood-testis barrier (BTB) in the testis of mice by using Aperio program

The present study found that bifenthrin insecticide has great effects on N-cadherin of BTB in the testis of mice which recorded low values as compare to untreated mice this mean that N-cadherin has pivotal role in testis development of BTB this result is agree with other researchers who found that the BTB is created by tight and adhesive junctional proteins, ectoplasmic specializations as desmosomes (cadherin), existing adjacent supporting cells [30]. The present study reveals that there was irreversible disturb histomorphometric structures of ST and BTB by effect of Bifenthrin insecticide minced diet this disagree with certain researcher who including the firmly affecting intercellular interactions of the testis so as to regulate the advance the safe male contraceptive without hormonal application and reversible methods [31]. The present study found that great effects on N-cadherin of BTB in the testis of mice that has role in spermatogenesis which is the process by which spermatogonia grow into well-developed sperms in ST, by effect of the supporting Sertoli cells. It is obvious that this cadherin protein constituent has influence on the adhesion, development and increase numbers of tumor cells. The alteration in functions of cells is closely related to the aggressive and progressive aspect of tumor cells. This need expansion about the role of cadherin protein constituent in progression of tumors and infertility [32]. The N-cadherin has pivotal role in testis development of BTB that cooperates in the process of spermatogenesis. The normal BTB and Sertoli cell is important for spermatogenesis, Sub fertile or infertile animals are evidence if any function of this barrier is disturbed and perturbed of both cells. The bifenthrin insecticides as an endocrine disrupter material has great effects on spermatogenesis that leads to low spermatogonia in the basal and low spermatids in luminal part of ST in the testis. The bifenthrin insecticides reveal features of cell death (pyknosis nuclei, with foamy cytoplasm and unclear cell membrane outline. immunohistochemical expression of N-cadherin of blood-testis barrier (BTB) in the testis of mice can be evaluated by applying Aperio program software.

Author Contributions

All authors contributed equally.

Conflicts of interest

The authors declare no conflict of interest.

References

1. Stanton P. Regulation of the blood-testis barrier. In Seminars in cell & developmental biology. Academic Press, (2016); 59: 166-173.

2. Mruk D, Cheng CY. The mammalian blood-testis barrier: its biology and regulation. *Endocrine reviews*, (2015); 36(5): 564-591.
3. Griswold M. The central role of Sertoli cells in spermatogenesis. In *Seminars in cell & developmental biology*. Academic Press, (1998); 9(4): 411-416.
4. Moreira S, Pereira S, Seco-Rovira V, Oliveira P, Alves M, Pereira M. Pesticides and male fertility: A dangerous crosstalk. *Metabolites*, (2021); 11(12): 799.
5. Lie P, Cheng C, Mruk, D. The biology of the desmosome-like junction: a versatile anchoring junction and signal transducer in the seminiferous epithelium. *International review of cell and molecular biology*, (2011); 286: 223-269.
6. Aydin S, Billur D, Kizil S, Ozkavukcu S, Topal F, Aydos K, Erdemli E. Evaluation of blood-testis barrier integrity in terms of adhesion molecules in nonobstructive azoospermia. *Andrologia*, (2020); 52(7): e13636.
7. Mruk D, Cheng C. The mammalian blood-testis barrier: its biology and regulation. *Endocrine reviews*, (2015); 36(5): 564-591.
8. Hess R, De Franca L. Spermatogenesis and cycle of the seminiferous epithelium. *Molecular mechanisms in spermatogenesis*, (2009); 1-15.
9. Smith L, Walker W. The regulation of spermatogenesis by androgens. In *Seminars in cell & developmental biology*. Academic Press, (2014); 2-13: 30.
10. Wang R, Yeh S, Tzeng C, Chang C. Androgen receptor roles in spermatogenesis and fertility: lessons from testicular cell-specific androgen receptor knockout mice. *Endocrine reviews*, (2009); 30(2): 119-132.
11. Wheelock M , Shintani Y, Maeda M, Fukumoto Y, Johnson K. Cadherin switching. *Journal of cell science*, (2008); 121(6): 727-735.
12. Park H, Kim J, Lee R, Song H. Cisplatin induces apoptosis in mouse neonatal testes organ culture. *International Journal of Molecular Sciences*, (2022); 23(21): 13360.
13. O'Donnell L, Stanton P, de Kretser D. Endocrinology of the male reproductive system and spermatogenesis, (2015); 6(6): 45-67.
14. Moreira S, Pereira S, Seco-Rovira, V, Oliveira P, Alves M, Pereira M. Pesticides and male fertility: A dangerous crosstalk. *Metabolites*, (2021); 11(12): 799.
15. Yawer A, Sychrová E, Labohá P, Raška J, Jambor T, Babica P, Sovadinová I. Endocrine-disrupting chemicals rapidly affect intercellular signaling in Leydig cells. *Toxicology and Applied Pharmacology*, (2020); 404: 115177.
16. Rato L, Alves M, Socorro S, Duarte A, Cavaco J, Oliveira P. Metabolic regulation is important for spermatogenesis. *Nature Reviews Urology*, (2012); 9(6): 330-338.
17. Cardoso A, Alves M, Mathur P, Oliveira P, Cavaco J, Rato L. Obesogens and male fertility. *Obesity Reviews*, (2017); 18(1): 109-125.
18. Babakhanzadeh E, Nazari M, Ghasemifar S, Khodadadian A. Some of the factors involved in male infertility: a prospective review. *International journal of general medicine*, (2020); 29-41.
19. Urióstegui-Acosta M, Tello-Mora P, de Jesús Solís-Heredia M, Ortega-Olvera J M, Piña-Guzmán B, Martín-Tapia D, Quintanilla-Vega B. Methyl parathion causes genetic damage in sperm and disrupts the permeability of the blood-testis barrier by an oxidant mechanism in mice. *Toxicology*, (2020); 438: 152463.
20. Ham J, You S, Lim W, Song G. Bifenthrin impairs the functions of Leydig and Sertoli cells in mice via mitochondrion-endoplasmic reticulum dysregulation. *Environmental Pollution*, (2020); 266: 115174.
21. Wang Q, Wang H, Shen J, Zhan R, Hong J, Li Z, Xu L. The anti-androgenic effects of cypermethrin mediated by non-classical testosterone pathway activation of mitogen-activated protein kinase cascade in mouse Sertoli cells. *Ecotoxicology and Environmental Safety*, (2019); 177: 58-65.
22. Erthal R, Staurengo-Ferrari V, Luiz K, Cunha F, Pescim R, Fernandes G. A. Exposure to low doses of malathion during juvenile and peripubertal periods impairs testicular and sperm parameters in rats: role of oxidative stress and testosterone. *Reproductive Toxicology*, (2020); 96: 17-26.
23. Ali W, Ma Y, Zhu J, Zou H, Liu Z. Mechanisms of cadmium-induced testicular injury: A risk to male fertility. *Cells*, (2022); 11(22): 3601.
24. Hashim Z, Kareem H, Jaafar H. The Evaluation of Placental Vascular Generation and Placental Apoptosis in Preterm and Post-date Placentae in Relation to Apgar Score at Birth. *Medical Journal of Babylon*, (2016); 13(1): 79-84.
25. Taeheh S, Jaafar H T, Jaafar H A, Jarullah H A. Effects of Dark-Light Cycle on the Histological and Immunohistochemical P73 Marker Expression of Cajal Cells in the Cerebral Cortex of Mice. *HIV Nursing*, (2023); 23(3): 2098-2106.
26. Wei C, Wang X, Yao X, Xi F, He Y, Xu Y, Yu T. Bifenthrin induces fat deposition by improving fatty acid uptake and inhibiting lipolysis in mice. *Journal of agricultural and food chemistry*, (2019); 67(51): 14048-14055.
27. Ong-Artborirak P, Boonchieng,W. Juntarawijit,Y, Juntarawijit C. Potential effects on mental health status associated with occupational exposure to pesticides among Thai farmers. *International Journal of Environmental Research and Public Health*, (2022); 19(15): 9654.
28. Khan N, Kennedy A, Cotton J, Brumby S. A pest to mental health? Exploring the link between exposure to agrichemicals in farmers and mental health. *International journal of environmental research and public health*, (2019); 16(8): 1327.
29. Titi-Lartey O, Khan Y. *Embryology, testicle*, (2020); 5(8): 44-89.
30. Hadi U, Jaafar H. The Effect Of Light/Dark Cycle On Blood Follicular Barrier Laminin Expression In Ovary Of The Mice. *Biochemical & Cellular Archives*, (2019); 19(2).
31. Mruk D, Cheng C. Sertoli-Sertoli and Sertoli-germ cell interactions and their significance in germ cell movement in the seminiferous epithelium during spermatogenesis. *Endocrine reviews*, (2004); 25(5): 747-806.
32. Mruk D, Cheng C. The mammalian blood-testis barrier: its biology and regulation. *Endocrine reviews*, (2015); 36(5): 564-591.



This work is licensed under a Creative Commons Attribution-NonCommercial 4.0 International License. To read the copy of this license please visit: <https://creativecommons.org/licenses/by-nc/4.0/>